

A NEW APPROACH TO THE HIP FOR REVISION SURGERY

D. J. W. McMINN, P. ROBERTS, G. R. FORWARD

From the Royal Orthopaedic Hospital, Birmingham

A new approach to the hip is described that allows better exposure for difficult revision surgery without the need for trochanteric osteotomy.

A V-shaped myofascial flap consisting of the proximal part of vastus lateralis and its fascia with gluteus medius and minimus, is reflected off the greater trochanter and proximal femur giving access to the entire capsule of the hip.

If the leg has been significantly lengthened by the revision procedure, abductor tension can be adjusted at closure by altering the reattachment of the flap, analogous to a V-Y-plasty.

Revision hip surgery requires wide exposure to allow adequate visualisation of the entire acetabulum and proximal femur. Exposure of the acetabulum and mobilisation of the femur is often extremely difficult because of dense scar tissue consequent upon previous surgery or infection.

Approaches commonly used for primary hip surgery, such as the posterior, direct lateral or anterolateral permit limited exposure which may be inadequate for a difficult revision case. The use of trochanteric osteotomy has been advocated because it facilitates exposure and acceptable rates of trochanteric union can be achieved (Wroblewski and Shelley 1985). However, Pellicci et al (1982) reported complications related to the trochanter in 13.6% of revision cases. Amstutz et al (1982) and Callaghan et al (1985) reported trochanteric nonunion rates of 12% and 9.3% respectively following revision surgery. Abductor dysfunction associated with trochanteric nonunion and displacement may jeopardise hip stability and impair functional recovery. Amstutz and Maki (1978) found that abductor weakness correlated with the amount of displacement of the trochanter and Nutton and Checketts (1984) demonstrated that trochanteric displacement of more than 3 cm caused significant abductor weakness and was associated with a poor result following primary

hip surgery. Kavanagh, Ilstrup and Fitzgerald (1985) reported that the incidence of dislocation following revision surgery was significantly greater in patients with nonunion of the trochanter (25%) than in those who either had not had a trochanteric osteotomy (9.1%) or had union of the trochanter (8.7%).

We report on a new surgical approach that provides excellent access to the hip for difficult revision surgery without the problems associated with trochanteric osteotomy.

PATIENTS AND METHODS

Operative technique. The patient is placed in the lateral position lying on the unaffected side. The approach is essentially lateral but the skin incision should, whenever possible, utilise previous surgical scars. The fascia lata and gluteus maximus fascia are identified and divided longitudinally. Great care is taken to preserve the anterior and posterior flaps of deep fascia which are often adherent from previous surgery.

The anterior and posterior margins of gluteus medius are defined. Vastus lateralis is incised to create a V-shaped flap with its apex distally (Fig. 1). This flap is developed proximally by subperiosteal reflection of the insertion of gluteus medius and minimus using a scalpel. The tendinous insertion of gluteus medius is thin posteriorly and care must be taken to preserve the flap in this area.

A strong myofascial flap is thus elevated from the proximal femur. Proximal retraction of this flap and division of the short external rotators provides unimpeded access to the whole capsule of the hip. Appropriate capsulectomy and, if required, the release of the tendons of gluteus maximus and psoas further mobilise the proximal femur. At the end of the procedure the leg is

D. J. W. McMinn, FRCS, Consultant Orthopaedic Surgeon
P. Roberts, MA, FRCS, Senior Orthopaedic Registrar
Royal Orthopaedic Hospital, Woodlands, Northfield, Birmingham B31 2AP, England.

G. R. Forward, MB BS, Senior Orthopaedic Registrar
Harlow Wood Orthopaedic Hospital, Harlow Wood, near Mansfield,
Notts NG18 4TH, England.

Correspondence should be sent to Mr P. Roberts.

© 1991 British Editorial Society of Bone and Joint Surgery
0301-620X/91/6223 \$2.00
J Bone Joint Surg [Br] 1991; 73-B: 899-901.

fully abducted, the flap replaced and sutured to the investing fascia of vastus lateralis. If the leg has been significantly lengthened by the revision procedure the flap can be repaired as a V-Y-plasty (Fig. 2).

Postoperatively the patient is kept in bed for three weeks with the leg in abduction.

Patients. This approach has been used for 25 of the last 100 revision hip arthroplasties carried out by the senior author (DJWM). It has been reserved for difficult revision cases when a particularly wide exposure was required or the hip was very stiff. 'Routine' hip revisions have been carried out through a posterior approach.

The mean age of the patients was 63 years (range 35 to 90). The mean number of previous operations the patients had undergone on the hip was 1.9 (range 1 to 5). Eleven hips were revised for aseptic loosening of one or both components; ten hips were revised for proven active infection, six by one-stage exchange and four in two stages. Four hips were revised from an established Girdlestone excision arthroplasty of which three had previously been infected.

RESULTS

Excellent exposure was achieved in all cases. A sound reattachment of the flap to the vastus lateralis fascia was made in all but one case. This patient required a proximal femoral replacement with a custom-made prosthesis for extensive bone loss. Vastus lateralis fascia was of poor quality so the flap was reattached to the deep surface of the fascia lata. In the four cases in which a two-stage exchange was carried out, the flap was found to have become firmly reattached to the trochanter at the second stage procedure.

There have been two cases of dislocation (8%). One

of these patients required re-revision of the acetabular component for malalignment and the hip has since been stable. The other had a proximal femoral replacement that dislocated on two occasions but had no detectable malalignment and was treated with intensive physiotherapy. He has remained symptom-free with no further episodes of dislocation over the last seven months.

Functional assessment has been made on 16 patients who are now more than six months after revision surgery; 13 of these have active abduction of power grade 4 or 5 (MRC scale), the other three have power of grade 3. Five patients have a positive Trendelenburg sign, six are fatigue positive (two at 10 to 20 sec, three at 20 to 30 sec and one at 50 sec) and five are negative. No patient had a decrease in abductor power following revision surgery using this approach.

DISCUSSION

This approach, like that of McFarland and Osborne (1954) and Hardinge (1982) is based on the anatomical observation that vastus lateralis and gluteus medius are in functional continuity over the greater trochanter and that their tendons can be raised intact from it. In this approach the flap, consisting of the belly and tendon of gluteus medius and of minimus and part of the belly of vastus lateralis with overlying fascia, is reflected proximally off the greater trochanter.

For revision surgery to be carried out safely it is essential that the entire acetabulum can be seen and that the proximal femur can be brought out of the wound to facilitate removal of femoral cement. This approach satisfies these requirements and provides an exposure comparable to that achieved by trochanteric osteotomy without the problems associated with nonunion and

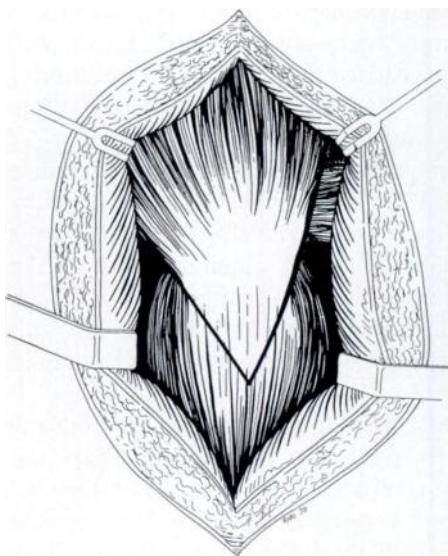


Fig. 1

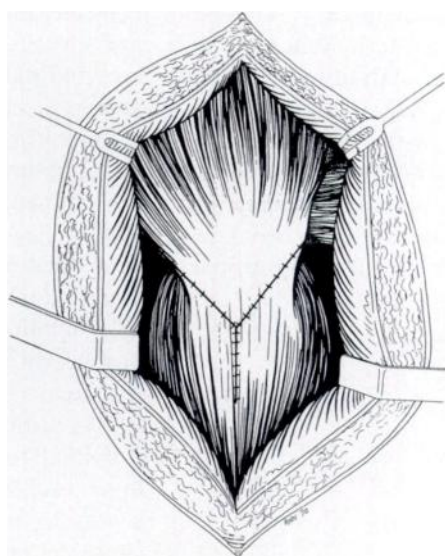


Fig. 2

Figure 1 - The incision used to create the myofascial flap. Figure 2 - Repair of the flap when the leg has been significantly lengthened.

displacement of the trochanter. In addition it allows abductor muscle tension to be adjusted if the leg has been significantly lengthened. This is not always possible following trochanteric osteotomy, particularly if the abductors are scarred or if the bone bed on the femur is of poor quality.

Reattachment of the flap to the investing fascia of vastus lateralis gives a strong repair which does not weaken abductor power. The rate of dislocation following this approach is similar to that reported in other series of revision cases (Callaghan et al 1985; Kavanagh et al 1985).

We recommend this technique when a wide exposure is needed for a difficult revision case. It is of particular value when the hip is stiff after multiple previous surgical procedures or infection.

No benefits in any form have been received or will be received from a commercial party related directly or indirectly to the subject of this article.

REFERENCES

- Amstutz HC, Maki S.** Complications of trochanteric osteotomy in total hip replacement. *J Bone Joint Surg [Am]* 1978; 60-A:214-6.
- Amstutz HC, Ma SM, Jinnah RH, Mai L.** Revision of aseptic loose total hip arthroplasties. *Clin Orthop* 1982; 170:21-33.
- Callaghan JJ, Salvati EA, Pellicci PM, Wilson PD Jr, Ranawat CS.** Results of revision for mechanical failure after cemented total hip replacement, 1979 to 1982: a two to five-year follow-up. *J Bone Joint Surg [Am]* 1985; 67-A:1074-85.
- Hardinge K.** The direct lateral approach to the hip. *J Bone Joint Surg [Br]* 1982; 64-B:17-9.
- Kavanagh BF, Ilstrup DM, Fitzgerald RH Jr.** Revision total hip arthroplasty. *J Bone Joint Surg [Am]* 1985; 67-A:517-26.
- McFarland B, Osborne G.** Approach to the hip: a suggested improvement on Kocher's method. *J Bone Joint Surg [Br]* 1954; 36-B:364-7.
- Nutton RW, Checketts RG.** The effects of trochanteric osteotomy on abductor power. *J Bone Joint Surg [Br]* 1984; 66-B:180-3.
- Pellicci PM, Wilson PD Jr, Sledge CB, et al.** Revision total hip arthroplasty. *Clin Orthop* 1982; 170:34-41.
- Wroblewski BM, Shelley P.** Reattachment of the greater trochanter after hip replacement. *J Bone Joint Surg [Am]* 1985; 67-A:736-40.